



# Evaluation and Treatment of Common Shoulder Conditions

**Ryan C. Rauck, MD**

*Assistant Professor of Orthopaedic Surgery  
Sports Medicine, Shoulder & Elbow Surgery  
Team Physician – OSU Department of Athletics  
The Ohio State University Wexner Medical Center*

**MedNet21**  
Center for Continuing Medical Education

 **THE OHIO STATE UNIVERSITY**  
WEXNER MEDICAL CENTER

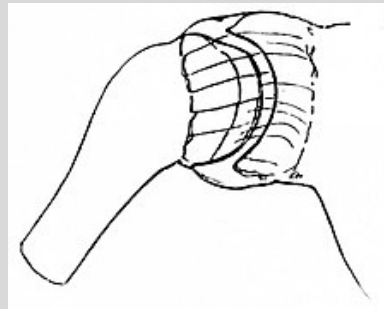
## Disclosures

- I have nothing to disclose

## Outline

- Anatomy
- Evaluation
- Imaging
- Examination
- Rotator cuff tears
- Frozen Shoulder
- Glenohumeral Arthritis
- Biceps Labral Complex Injuries
- Instability

## Shoulder



- “Endeavour to determine the exact site of the patient’s pain: this can be difficult”

- Brukner and Khan

<https://commons.wikimedia.org/>

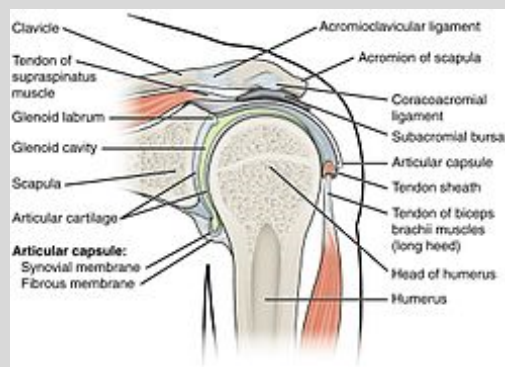
## Glenohumeral Joint

- Shallow (“golf ball sitting on a tee”)
  - Inherently unstable (maximizes ROM)



<https://commons.wikimedia.org/>

- Static stabilizers
  - Glenohumeral ligaments, glenoid labrum and capsule
- Dynamic stabilizers
  - Predominantly rotator cuff muscles
  - Also scapular stabilizers
    - Trapezius, levator scapulae, serratus anterior, rhomboids



<https://openstax.org/books/anatomy-and-physiology/pages/1-introduction>

## The Rotator Cuff Muscles: SITS

- Supraspinatus ABD
- Infraspinatus ER
- Teres minor ER
- Supscapularis IR

Depress humeral head against glenoid to allow full abduction

## Common Shoulder Pathologies

- **Acromioclavicular**
  - Separation
  - Arthrosis
  - Distal clavicle osteolysis
- **Rotator Cuff**
  - Tendinopathy/Tear
  - Impingement
  - Bursitis
- **Joint pathology**
  - Adhesive Capsulitis
  - GH arthrosis
  - Instability
- **Bicep/labral**
  - Tendinopathy
  - Glenoid Labral Tears
- **Scapular dyskinesis**

**HISTORY AND EXAM ARE FAR MORE IMPORTANT THAN IMAGING**

## Clues from history as to etiology of pain (location)

- **Anterior**
  - Long head biceps
  - Subscapularis
  - Pec major
- **Superior**
  - AC joint
    - OA, DCO, separation
- **Posterior**
  - Scapular dyskinesis
  - Tight posterior shoulder muscles
  - Tight posterior capsule
- **Lateral**
  - Rotator cuff (patch sign)
- **Deep**
  - Labral tear
  - GH arthritis
  - Adhesive capsulitis



<https://commons.wikimedia.org/>

## Clues from history as to etiology of pain: Age

### • 14-25

- Labral tears
- RTC impingement
- Scapular dyskinesis
- AC separation
- GH dislocation
- DCO



### • 25-55

- RTC impingement/partial tear
- Adhesive capsulitis
  - Female, DM, hypothyroid
- Scapular dyskinesis

### • >55

- RTC tears
- GH arthritis
- AC arthritis

## Clues from history as to etiology of pain:

### MOI

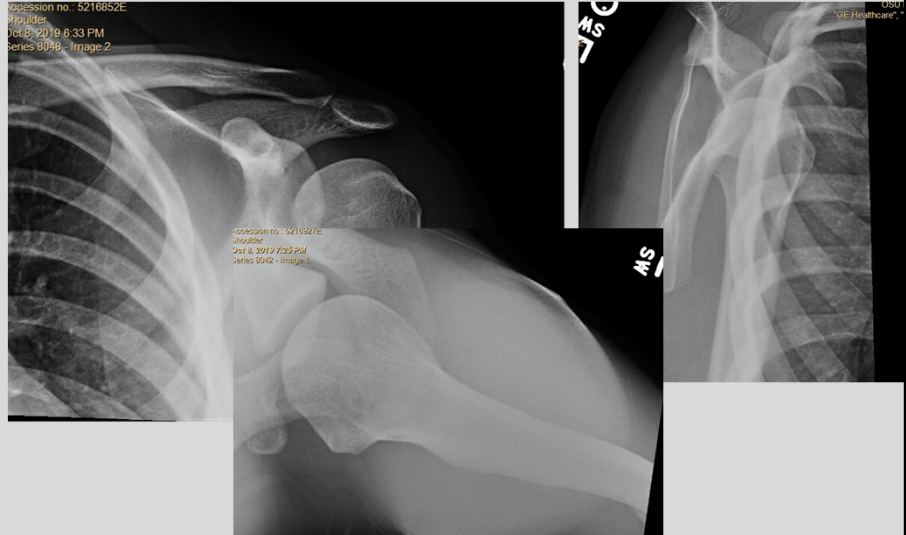
- **Overuse**
  - RTC impingement
  - LHB tenosynovitis
  - Labral tears
- **Post traumatic**
  - GH Dislocation
  - AC Separation
  - RTC tear
  - Proximal biceps tear
- **Insidious with poor posture**
  - Scapular dyskinesis
  - RTC impingement

### ROM

- **Decreased AROM/Full PROM**
  - RTC tendinitis and impingement
  - RTC tear
- **Decreased AROM and PROM**
  - GH arthritis
  - Adhesive capsulitis

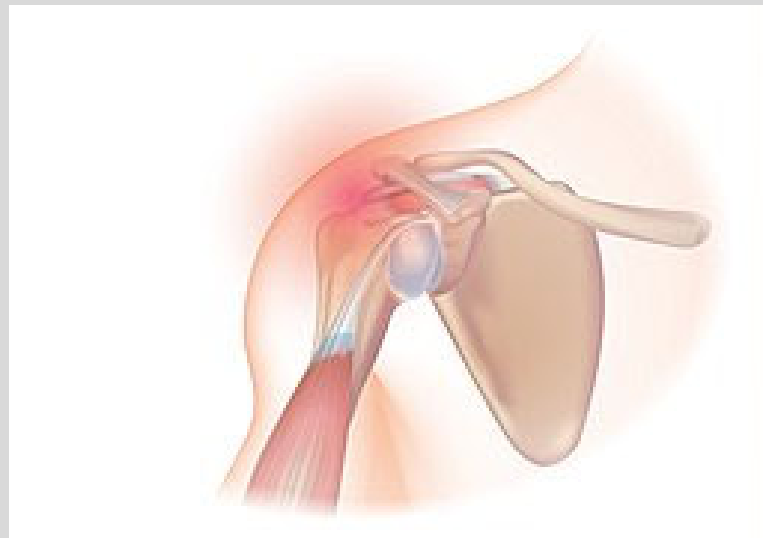
## Basic Radiographic Shoulder Views

- **AP:**
  - GH joint in natural anatomic position
- **Axillary**
- **True AP (Grashey):**
  - Prevents overlap of humeral head over glenoid
- **Scapular y view:**
  - Assist with alignment



## Examination

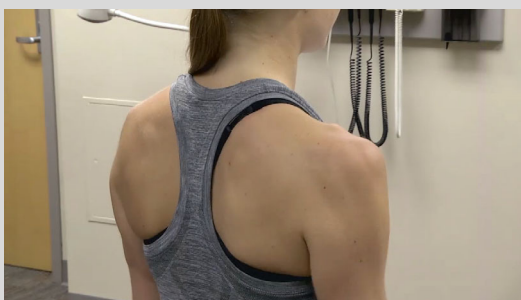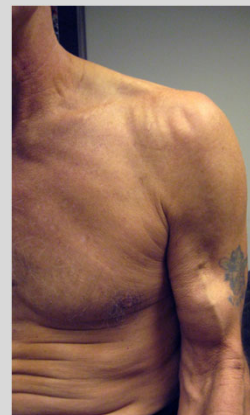
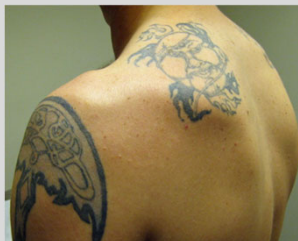- Inspection
- Palpation
- ROM
- Strength
- Special Tests



<https://commons.wikimedia.org>

## Physical Examination

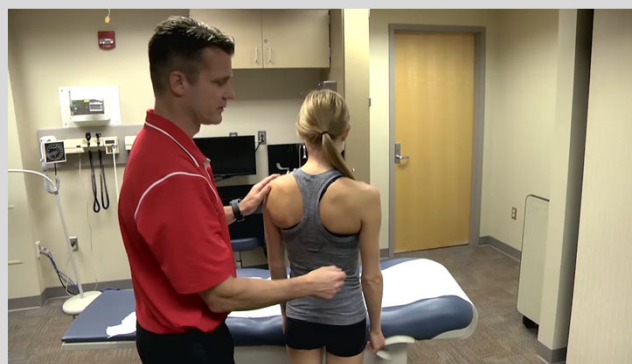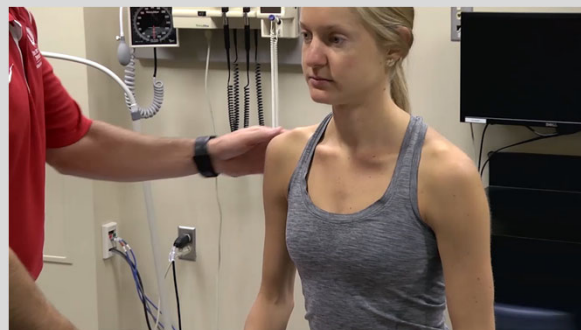- Visual Inspection
  - Muscle atrophy
  - Tear
- Scapular dyskinesis



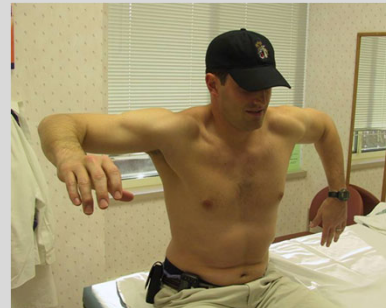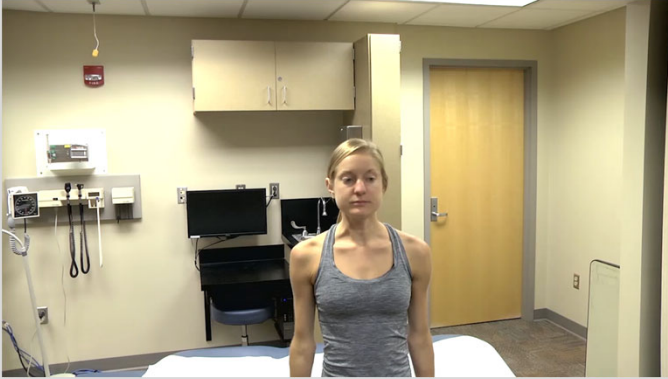13

## Palpation

- AC joint
- SC joint
- LHB
- RTC muscles
- Scapular stabilizing muscles

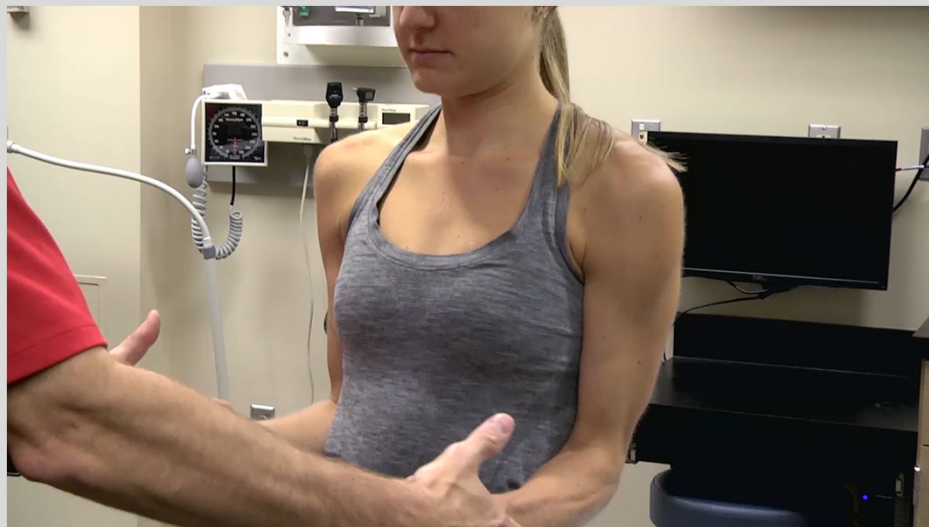

# ROM



<https://commons.wikimedia.org>

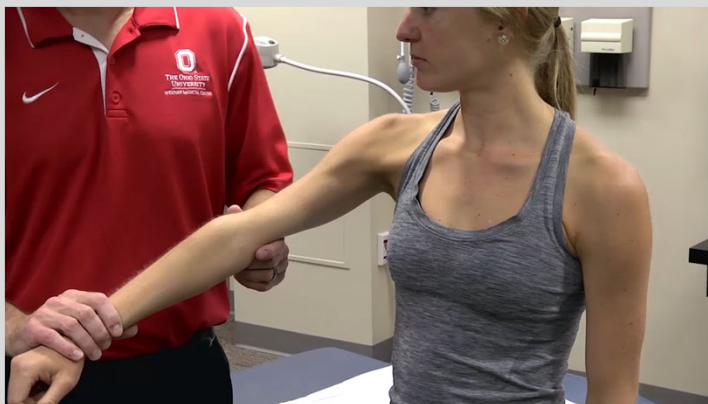# Strength





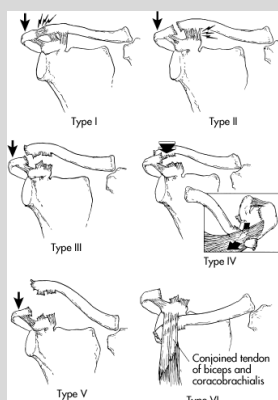
## Acromioclavicular joint

- History:
  - Acute: Direct blow to lateral shoulder, FOOSH,
  - Chronic: Distal clavicle osteolysis, arthrosis
- Exam:
  - AC joint TTP (Paxino's)
  - Cross arm adduction pain
  - Compression
- Radiographic evaluation
  - Stress (weighted)
  - Comparison
  - Cephalad angle view (Zanca)



## Acromioclavicular (A-C) Sprain

### Rockwood Classification



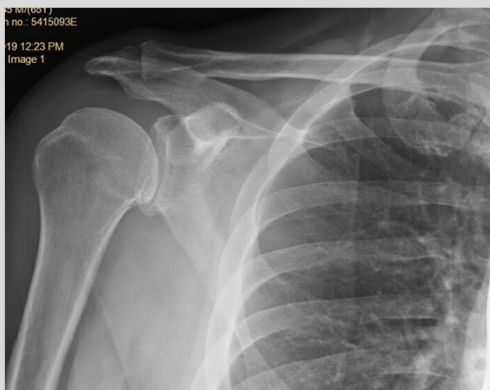
### Presentation

- Damage to A-C joint ligaments
- Pain and/or deformity over A-C joint
- Graded I-VI
  - I-III usually treated non-operatively
  - IV-VI referred to orthopedic surgery
  - **X ray: Zanca view**

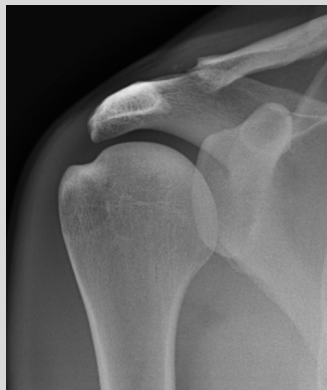Treatment: brief sling, rest, ice, NSAIDs, PT for early motion, 3-12 week return to activity  
Surgery for high grade or if nonop fails

## AC joint

### Arthrosis



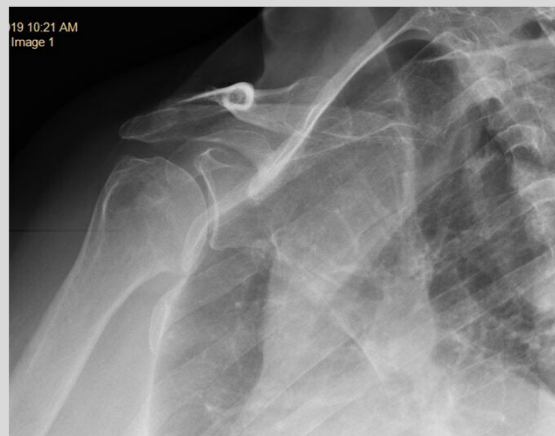### Distal Clavicle Osteolysis



Treatment: nonoperative: NSAIDs, PT, ultrasound-guided injection  
Surgery to remove 8-10mm of distal clavicle if nonop fails

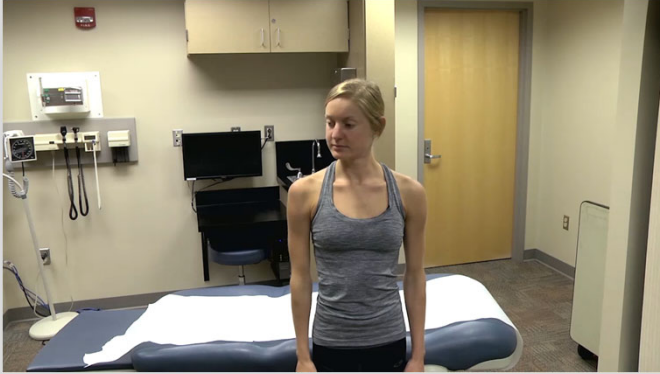
## Rotator Cuff Impingement/Tendinitis

- History
  - Lateral shoulder pain (patch sign)
  - Sometimes anterior/posterior pain
  - Pain overhead
  - Pain at night
  - No significant weakness (but pain)
- Physical Examination
  - Impingement testing
  - Scapular dyskinesia



**Treatment:** nonoperative: NSAIDs, PT, subacromial injection  
Surgery for subacromial decompression if nonop fails

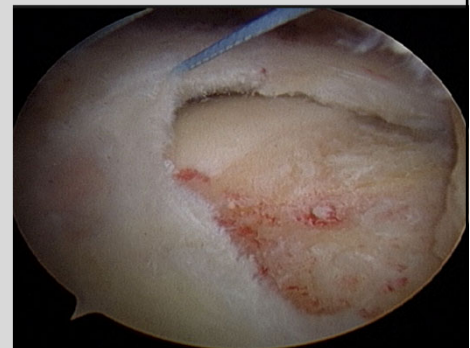
## Impingement tests



- Jobe's (Empty Can)
- Hawkins
- Neers

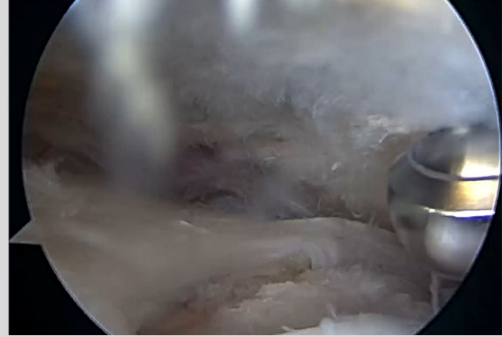## Rotator Cuff Tear

- Rotator cuff tears are common in patients >60 years
  - MRI studies have found high rates (>30%) of rotator cuff tears in asymptomatic patients
- What does this mean?
  - Just because an MRI says a patient has a rotator cuff tear doesn't mean they need surgery



## History

- Age, sex, dominant arm, activity level/goals?
- Night pain?
- Injury or degenerative/atraumatic
- Prior imaging
- Prior treatment
  - NSAIDs, Injections (steroid – where was it given)
  - Physical Therapy (how many visits; beneficial?)
  - Surgery

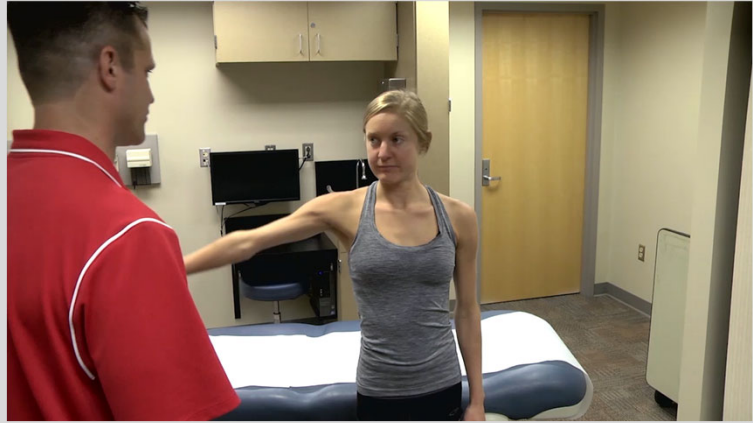


## Exam

- Pain with active ROM overhead
- Passive ROM > Active ROM (be careful...frozen shoulder)
- Weakness in cuff testing
- Positive empty can sign
- Check biceps, AC joint
- Make sure to examine their neck

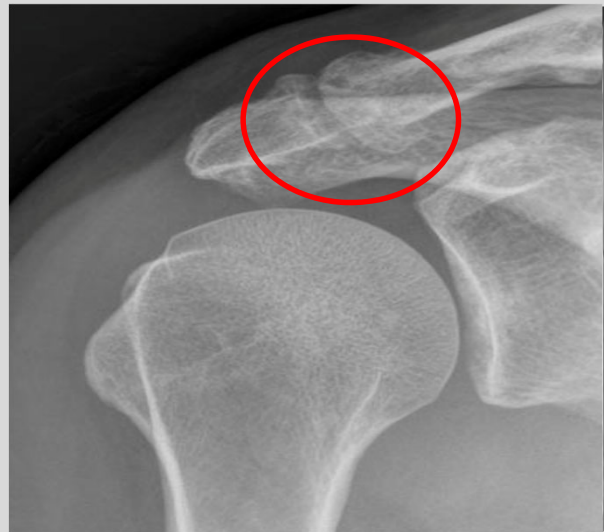## Rotator Cuff Tear

- Larger tears:
  - Drop Arm
  - External Rotation Lag sign



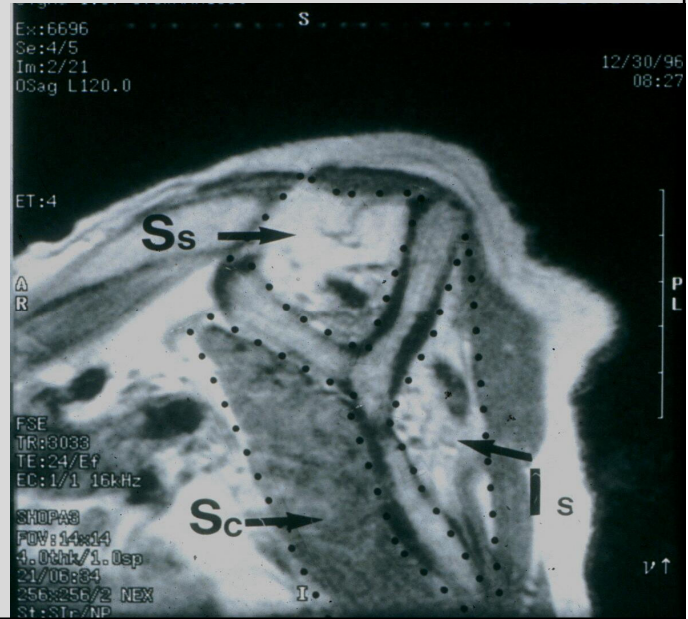## X-Rays

- Always start w/ X-Rays
- High-riding humeral head
- Inferior “beard” osteophyte
- Diseased AC joint



## MRI

- Tendon integrity
- Retraction
- Muscle Atrophy
- Associated findings:
  - Biceps
  - AC Joint
  - Cartilage



## Treatment

- Treatment is based on:
  - Patient's symptoms and goals + PE + Imaging
- Natural history: 50% of tears will progress over time
- Non-Operative
  - Partial thickness tears
  - Small full thickness tears
  - Chronic full thickness tears
- Operative
  - Acute, full thickness tears
  - Failed non-operative management

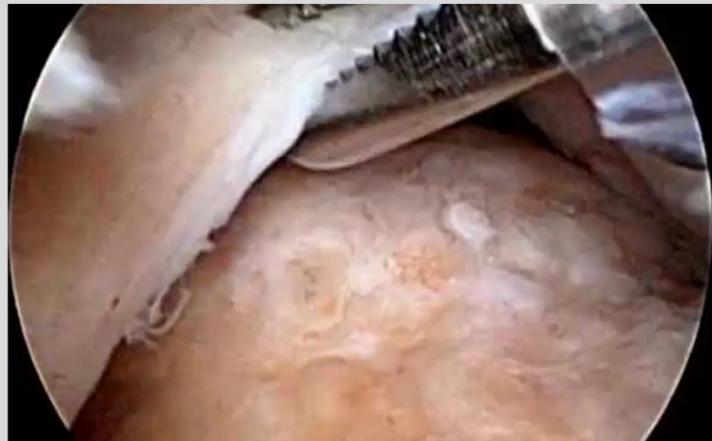

## Options for Non-Surgical Treatment

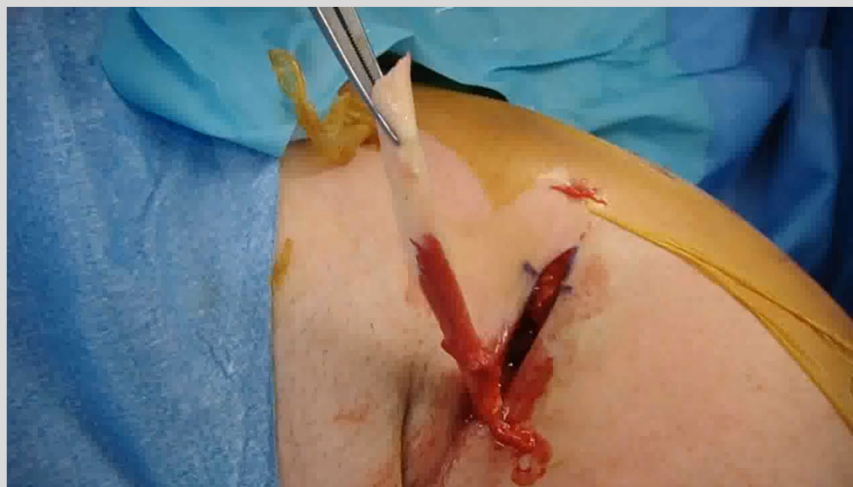- Physical Therapy
  - 2-3x/week for 4-6 weeks
  - ROM, modalities, scapular strengthening
- NSAIDS
- Injections
  - Corticosteroid
    - (No more than 3 injections per joint per year)
    - Recent studies showing worse outcomes following RCR following steroid shot
  - PRP
  - Others

## Options for Surgical Treatment

- Debridement +/- biceps tenotomy/tenodesis
- Rotator Cuff Repair
- Patch Augmentation
- Balloon Spacer
- Tendon Transfer
- Arthroplasty



## Pain Generator



<https://commons.wikimedia.org>

## Rotator Cuff Repair

- What is it?
  - Arthroscopic surgery
  - Rotator cuff is debrided and anchored back to bone
- Who will benefit from this?
  - Full thickness cuff tears
  - Partial thickness tears refractory to non-operative treatment
- How effective is this?
  - Very effective at relieving pain and restoring some function
  - Tendon heals about 50% of the time
  - Patients still do well even if tendon doesn't heal



COPYRIGHT © 2013 BY THE JOURNAL OF BONE AND JOINT SURGERY, INCORPORATED

### The Societal and Economic Value of Rotator Cuff Repair

Richard C. Mather III, MD, Lane Koenig, PhD, Daniel Acevedo, MD, Timothy M. Dall, MS, Paul Gallo, BS, Anthony Romeo, MD, John Tongue, MD, and Gerald Williams Jr, MD  
Investigation performed at KNG Health Consulting, Rockville, Maryland

**TABLE II Results of the Base Case: Mean Societal Impact of Rotator Cuff Repair\***

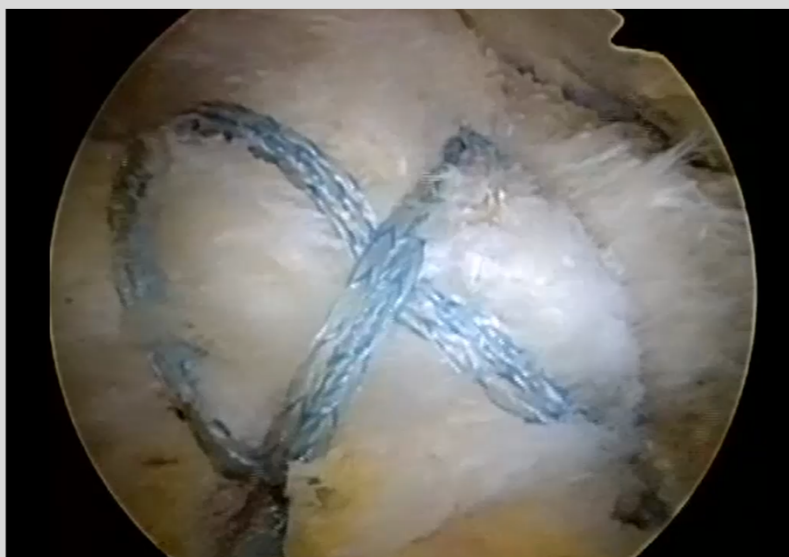
Age Group	Net Societal Savings (A)	QALY (B)	Incremental Cost-Effectiveness Ratio (A/B)
U.S. population	\$13,771	0.62	Dominant
30-39 yr	\$77,662	0.97	Dominant
40-49 yr	\$49,285	0.81	Dominant
50-59 yr	\$18,215	0.65	Dominant
60-69 yr	-\$5712	0.48	\$12,024/QALY
70-79 yr	-\$11,997	0.33	\$36,576/QALY

**Rotator Cuff Repair is Cost-effective for All Populations**

\*Net societal savings represent the difference in total lifetime costs (the direct costs of treatment and indirect costs, such as lost wages) between the rotator cuff repair and nonoperative treatment. Positive numbers represent economic savings, and negative numbers represent economic losses. A strategy is termed dominant when it is both less costly and more effective. All savings are expressed in 2013 U.S. dollars. QALY= quality-adjusted life year.

Mather RC 3rd, Koenig L, Acevedo D, Dall TM, Gallo P, Romeo A, Tongue J, Williams G Jr. The societal and economic value of rotator cuff repair. J Bone Joint Surg Am. 2013 Nov 20;95(22):1993-2000. doi: 10.2106/JBJS.L.01495. PMID: 24257656; PMCID: PMC3821158.

## Rotator Cuff Repair



## Post-Operative Rehabilitation

### Weeks 0-1:

Patient to do Home Exercises given post-op (pendulums, elbow ROM, wrist ROM, grip strengthening)  
Patient to remain in sling for 6 weeks

### Weeks 1-6:

True PROM only! The rotator cuff tendon needs to heal back into the bone  
ROM goals: 140° FF/40° ER at side; ABD max 60-80° without rotation  
No resisted motions of shoulder until 12 weeks post-op  
Grip strengthening  
No canes/pulleys until 6 weeks post-op, because these are active-assist exercises  
Heat before PT, ice after PT

## Post-Operative Rehabilitation

### Weeks 6-12:

Begin AAROM → AROM as tolerated - Light passive stretching at end ranges  
Begin scapular exercises, PRE's for large muscle groups (pecs, lats, etc)  
At 8 weeks, can begin strengthening/resisted motions  
Isometrics with arm at side beginning at 8 weeks

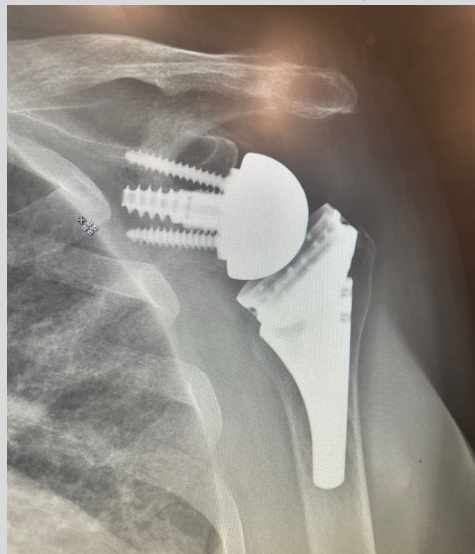
### Months 3-12:

Advance to full ROM as tolerated with passive stretching at end ranges  
Advance strengthening as tolerated: isometrics → bands → light weights (1-5 lbs); 8-12 reps/2-3 sets per rotator cuff, deltoid, and scapular stabilizers  
Only do strengthening 3x/week to avoid rotator cuff tendonitis  
Begin eccentrically resisted motions, plyometrics (ex. Weighted ball toss), proprioception (es. body blade)  
Begin sports related rehab at 4 ½ months, including advanced conditioning

When the Cuff Repair Heals, Results Are Better  
Many patients do well even if it doesn't fully heal

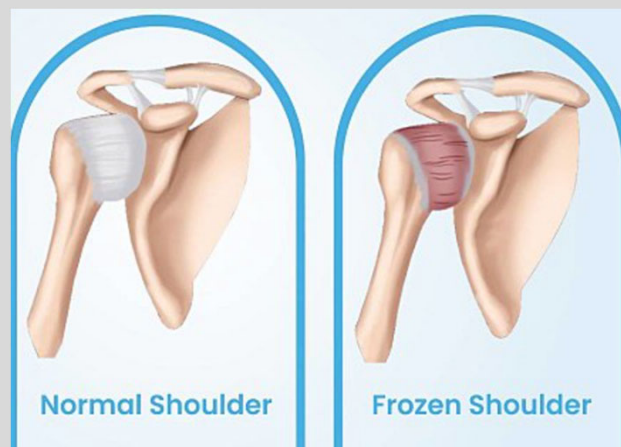
**If Irreparable tear or if All Else Fails...**

Reverse Shoulder Replacement



## Adhesive Capsulitis

- “Frozen Shoulder”
- History:
  - Pain
  - Decreased use/Immobility
  - Gradual stiffness
  - Often associated with
    - Female gender
    - DM
    - Hypothyroidism
- PE:
  - Decreased **BOTH** AROM and PROM
  - No arthritis on plain film
  - Feels tight
  - Patient is not guarding secondary to pain

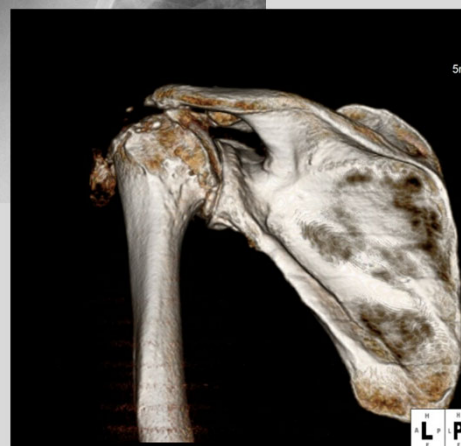
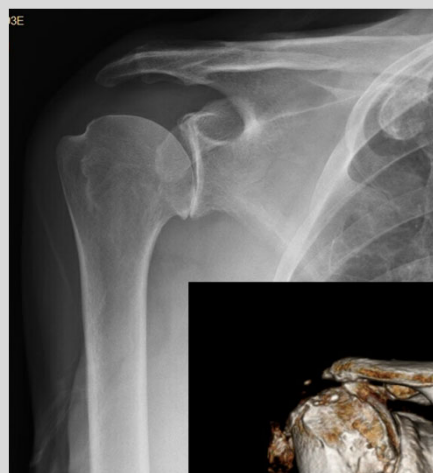
**Treatment:** nonoperative: NSAIDs, PT, US-guided GH injection  
Surgery for capsular release/manipulation if *prolonged* nonop fails

<https://commons.wikimedia.org>

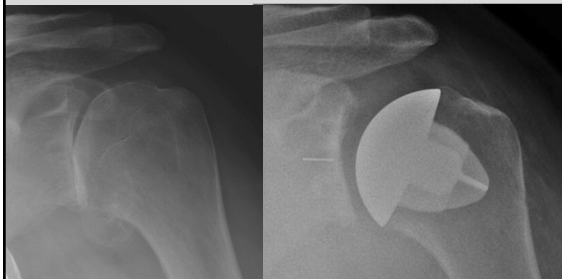
## Glenohumeral Arthritis

- History
  - Deep shoulder ache
  - Nighttime pain
  - Insidious onset
- Physical examination
  - Decreased AROM **and** PROM
- Radiographic evaluation
  - Glenohumeral joint space narrowing
  - Osteophytes
  - Sclerosis

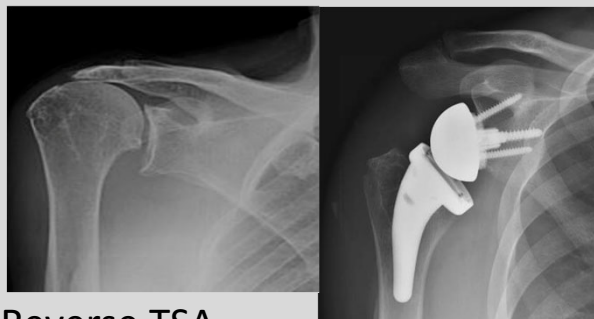

**Treatment:** nonoperative: NSAIDs, +/-PT, US-guided GH injection  
Surgery for shoulder replacement if nonop fails

## Shoulder Replacement: Anatomic and Reverse

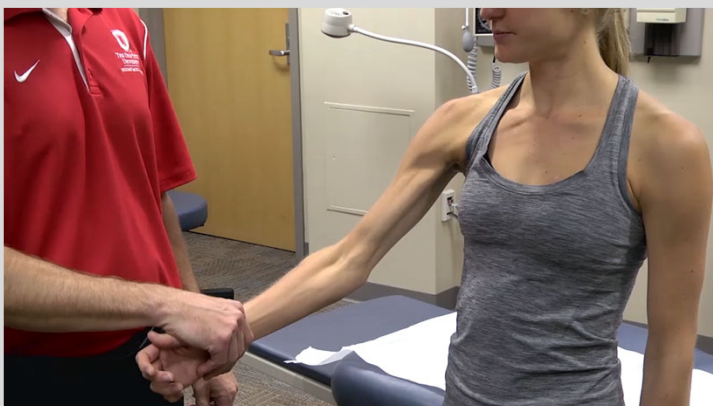

- Anatomic TSA
  - Glenohumeral arthritis
  - Must have intact rotator cuff



- Reverse TSA
  - “anything else”
  - Rotator cuff tear arthropathy
  - Certain fractures
  - Revision of failed anatomic
  - Failed rotator cuff repair
  - Older patients?

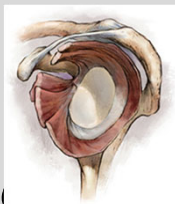
## Biceps Tendinitis



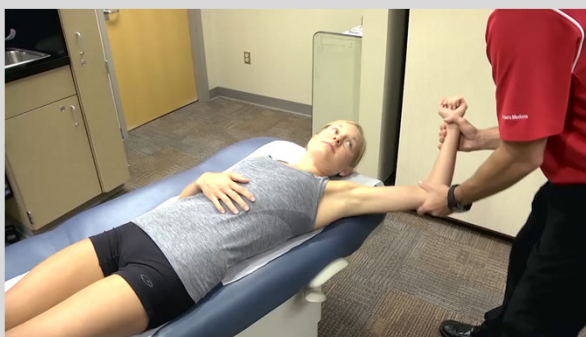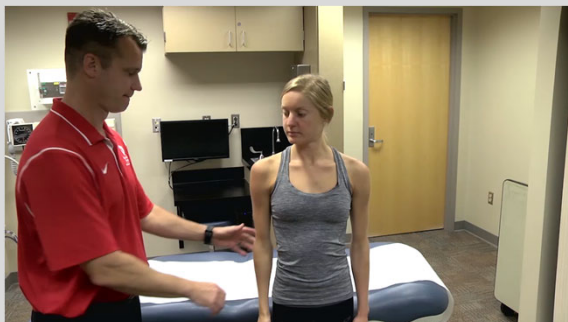**Treatment:** nonoperative: NSAIDs, PT, US-guided injection  
Surgery for biceps tenodesis if nonop fails

- Associated with:
  - Impingement
  - RTC tears
  - Tendon subluxation
- History:
  - Anterior Pain,
  - +/- snapping
- PE:
  - Biceps TTP
  - Speed’s test
  - Yergason’s test

## Superior Labrum (SLAP)



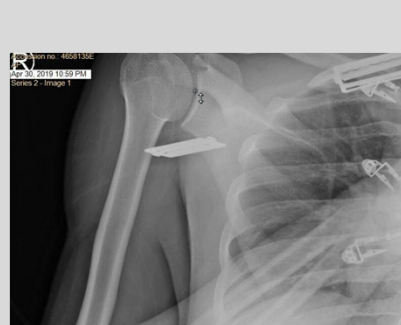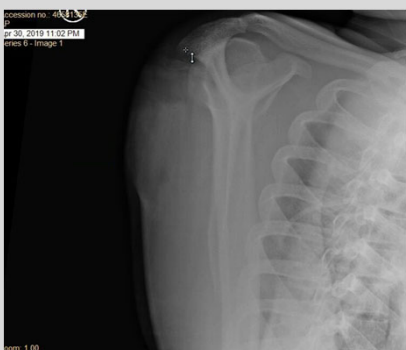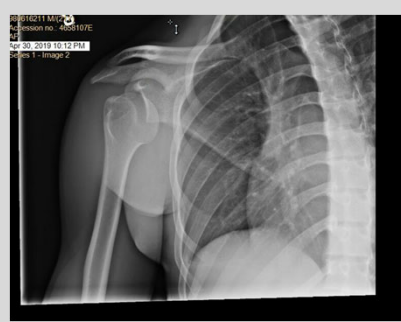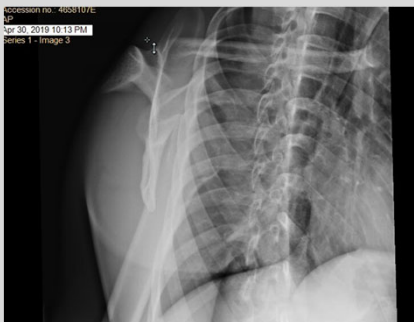
- Physical Examination
  - Deep shoulder pain
  - Popping
  - Special Tests:
    - O'Brien's
    - Dynamic labral shear test
      - O'Driscoll
    - Anterior slide
    - Crank



**Treatment:** nonoperative: NSAIDs, PT, US-guided injection  
Surgery for SLAP repair versus biceps tenodesis if nonop fails

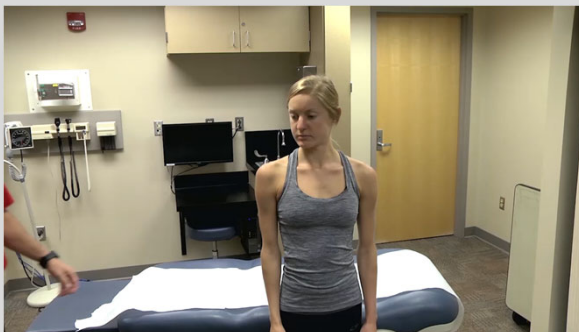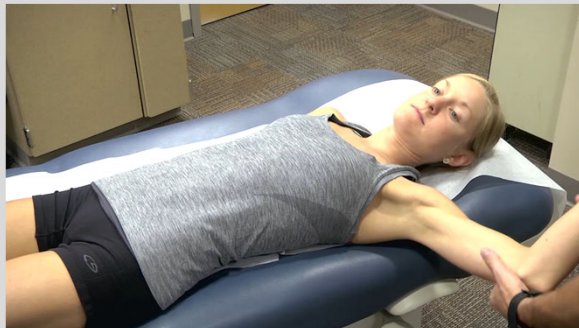## Shoulder Instability

- History
  - Post traumatic
  - Atraumatic
  - MOI: ER and ABD
- Radiographic evaluation
  - Plain films
  - Axillary view!!
  - MRI and/or CT



## Instability

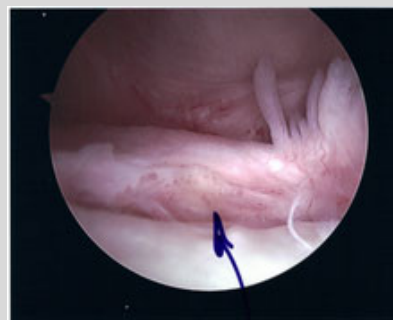
- Physical examination
  - Apprehension
  - Relocation
  - Sulcus sign
  - Load and shift



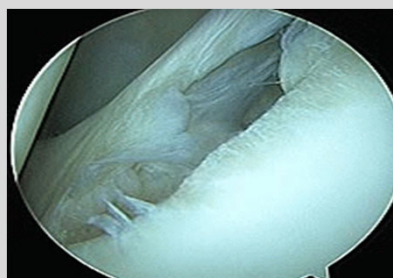
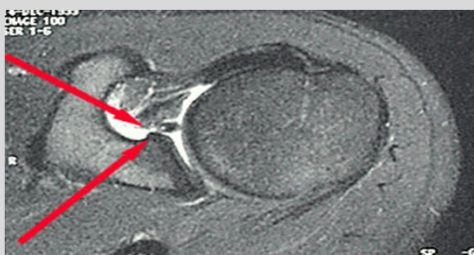
## Capsulolabral Avulsion

### *Initial Dislocation*

- Baker et al, 1990- 87%
- Norlin et al, 1993- 100%
- Taylor and Arciero, 1997- 97%
- Antonio et al, 2007- 73%
- Owens et al, 2010- 96%



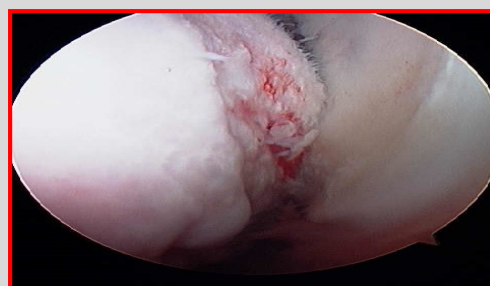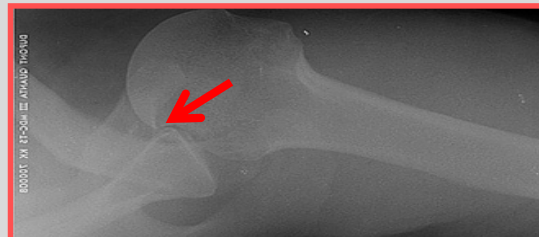<https://commons.wikimedia.org/>



## Humeral Pathology

### *Initial Dislocation*

- Hill-Sachs
  - 90%- Arciero, 1997
  - 100%- Kirkley, 1999
  - 56%- Larrain, 2001
  - 71%- Antonio, 2007
  - 93%- Owens, 2010



## Treatment

- Closed reduction immediately or under sedation in the ER
- Sling or sling and swathe for comfort; isometric exercises started
- 1-2 weeks post-injury: begin PT program
- Beware of co-existent rotator cuff tear in patients over 35 years of age- particularly subscapularis rupture; 15% incidence of rotator cuff tears in patients over 40 and 40% incidence in those >60
- Possible surgery in younger patients- recurrence rates high in patients under 20- 25 years of age
  - Robinson et al (2006)- patient ages 15-35 with primary dislocation: 55.7% recurrence within 2 years and 66.8% by 5 years; 86.7% recurrences occurred within 2 years; younger males have highest risk of recurrence



## Recurrent Instability *Predictors*

- Age
- Male Gender
- Bone Loss
  - Glenoid, humeral, or bipolar
- Activity level
  - Contact or collision sports

Prognostic factors	Points
Age at surgery (yrs)	
≤ 20	2
> 20	0
Degree of sport participation (pre-operative)	
Competitive	2
Recreational or none	0
Type of sport (pre-operative)	
Contact or forced overhead	1
Other	0
Shoulder hyperlaxity	
Shoulder hyperlaxity (anterior or inferior)	1
Normal laxity	0
Hill-Sachs on AP* radiograph	
Visible in external rotation	2
Not visible in external rotation	0
Glenoid loss of contour on AP radiograph	
Loss of contour	2
No lesion	0
Total (points)	10

Balg F, Boileau P. The instability severity index score. *J Bone Joint Surg Br.* 2007;89-B(11):1470-1477. doi:10.1302/0301-620X.89B11.18962



<https://commons.wikimedia.org/>

ISIS Score  
Boileau  
JBJS 2007

6 or more  
→  
70% failure  
Scope  
Bankart

Robinson, et al. JBJS, 2006  
Prognostic Level I Evidence

## In-Season Athlete

- Buss et al, *Am J Sports Med*, 2004.
  - 30 in-season episodes of instability
  - 26 (87%) returned
    - Average missed 10.2 days
  - 41% 2<sup>nd</sup> instability episode in season
    - 53% (16 pts) underwent surgery after season



## Longo et al, *Arthroscopy*, 2016

- Systematic review of surgical versus non-surgical management of patients 18 y.o. and younger with traumatic shoulder instability
- **71.3% on non-operative patients sustained a recurrent dislocation compared to 17.5% of surgical patients**
- **Higher return to sport with surgery versus no surgery- 71-93% versus 50-56%**

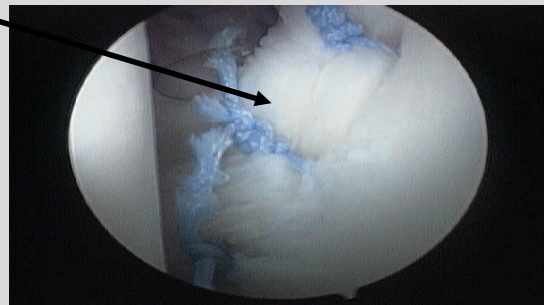
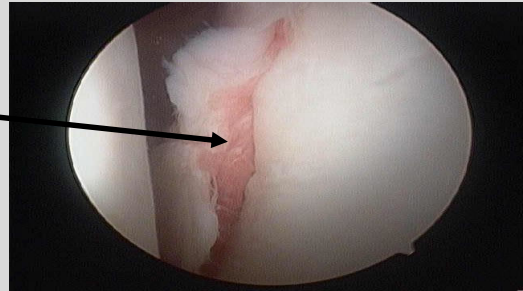
## So, Surgery after First Dislocation?

- **NOT TYPICALLY, BUT WORTH DISCUSSING**
  - Decision making is multi-factorial:
  - Provide athlete and family with solid information to make a informed decision
  - Remember: the young athlete is high risk!
  - But, immediate surgery is season ending!
  - Understand the risks of recurrent instability



## Bankart Repair

- Bankart lesion (tear of the anterior inferior labrum)
- Bankart repair with suture anchors

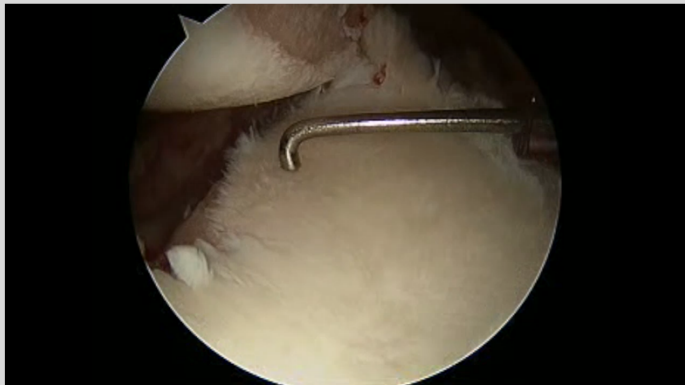


## Why did Arthroscopic Stabilization Fail?

- Patient factors
  - Young age
  - Males
  - Number of prior dislocations
  - Contact sports
  - Hyperlaxity
- Technical factors?
- Additional pathology
  - Glenoid bone loss
  - Humeral bone loss
  - Capsular laxity
  - Other (HAGL, etc)

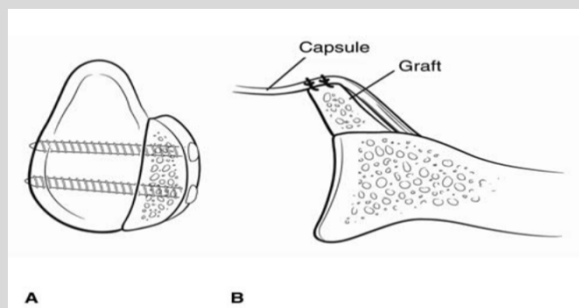
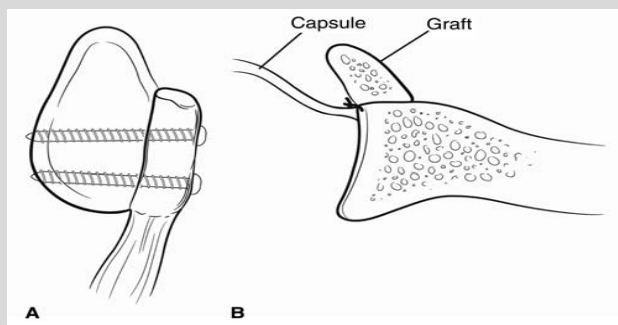
## Evaluation of Recurrent Instability

- Calculate % glenoid bone loss
  - 3D CT gold standard
- Determine on or off track
- Consider patient factors



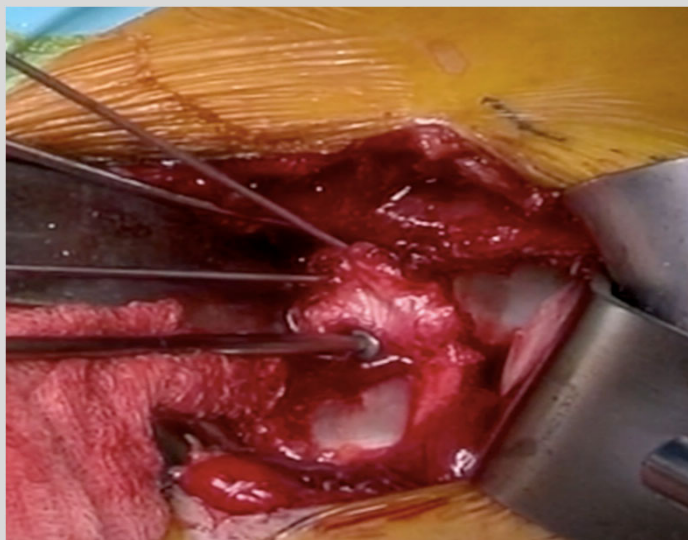
**Glenoid loss >10-15%, off track hill sachs, and/or high risk patient → Bony reconstruction anterior glenoid**

## Latarjet Procedure



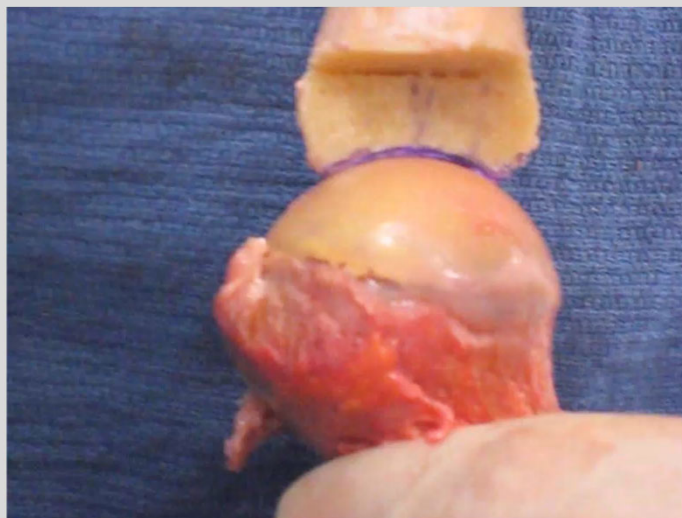## Latarjet

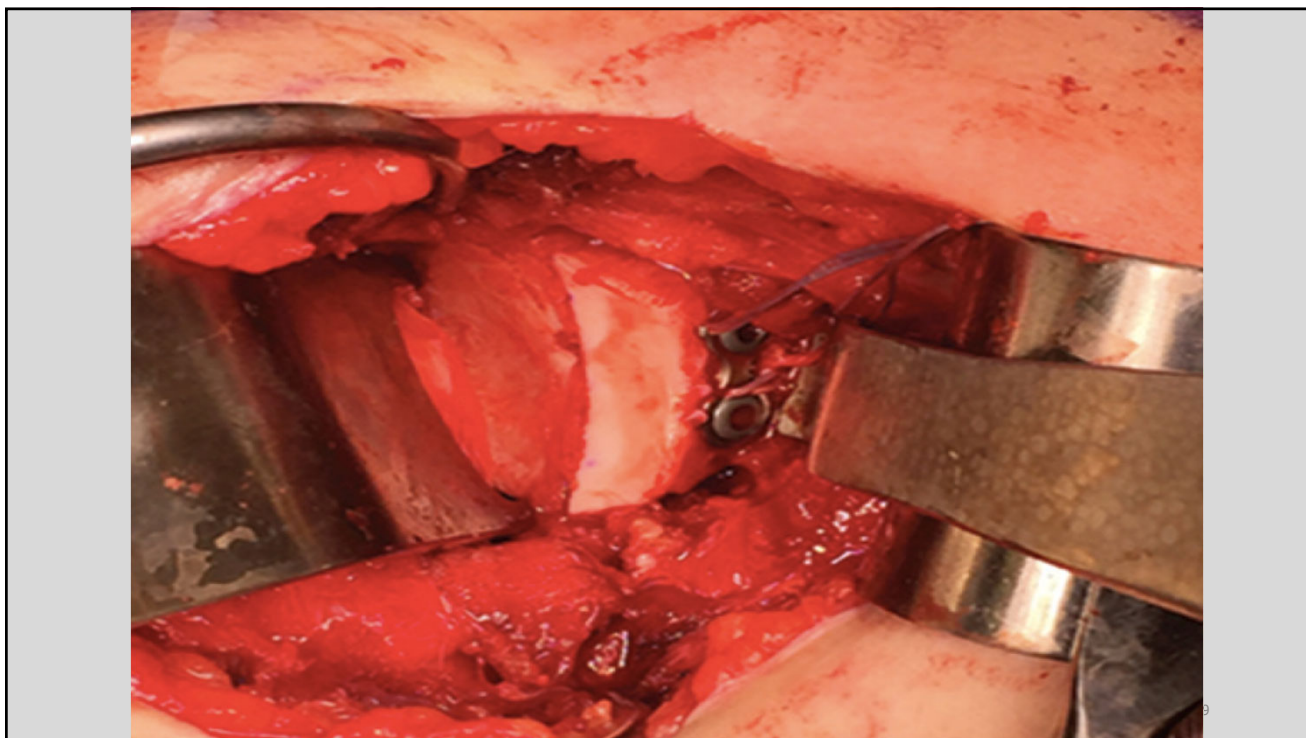
- Excellent track record for stability well over 90% at 10+ years
- Good/excellent and return to sport over 80%
- Complications 10 to 20% depending on series
- Arthritic changes in 38% at 10+ years
  - Damage from instability or non-cartilage coracoid reconstruction?



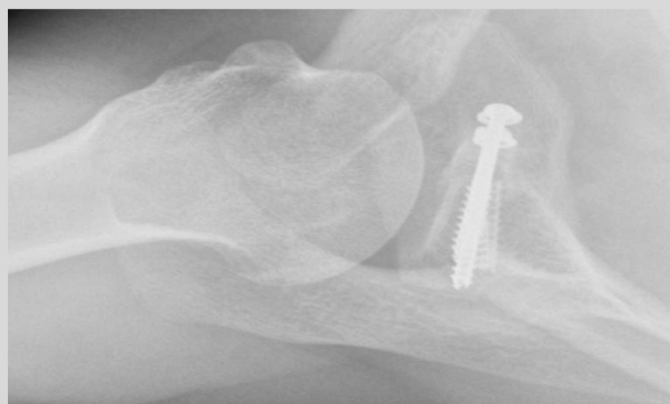
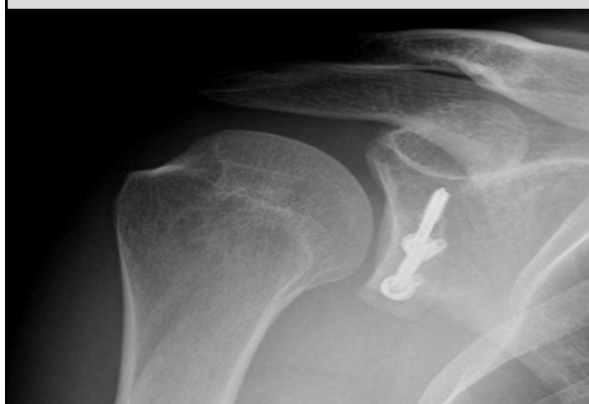## Distal Tibia Allograft (DTA)

- Excellent match to glenoid radius of curvature
- Restoration of cartilage surface
- Dense subchondral bone for screw fixation
- Downsides
  - Cost
  - No sling effect
  - Need for allograft healing to glenoid





## Postop after DTA Reconstruction

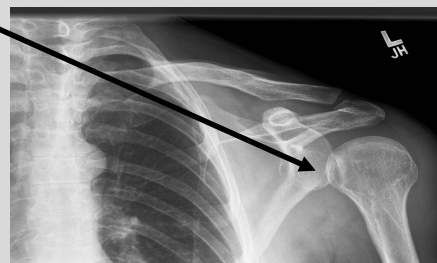
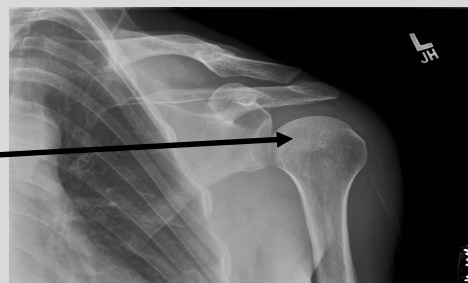


## Posterior Dislocation – DON'T MISS IT

- Adduction/internal rotation mechanism
- Seizures are common (electrocution)
- Shoulder cannot actively or passively externally rotate
- “Light bulb” sign of AP view
- ALWAYS GET AN AXILLARY VIEW- may be only view which demonstrates this type of dislocation

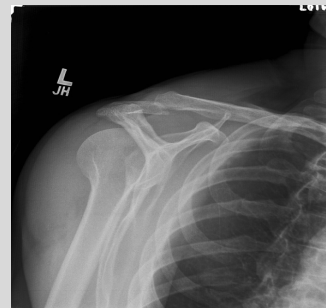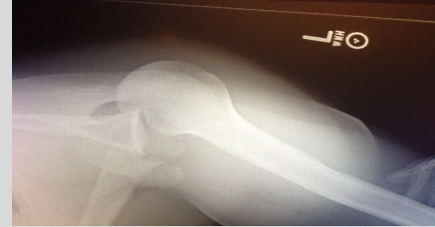### AP View of Posterior Dislocation “Light-Bulb Sign”

- Light-bulb sign (internally rotated humeral head) with overlap between the humeral head and glenoid indicative of a posterior shoulder dislocation.



## Outlet and Axillary Views of a Posterior Dislocation

- Axillary view with posterior humeral head dislocation
  - Glenoid
  - Humeral head
- Outlet view with posteriorly dislocated humeral head



## Treatment

- Closed reduction
- Arm is placed in gunslinger brace with the shoulder in slight abduction and external rotation for 4-6 weeks
- PT is started at 4-6 weeks




## Treatment

- Surgical treatment if shoulder is dislocated for greater than 2-3 weeks, large reverse Hill-Sachs lesion greater than 20% of humeral head
- Bone block procedure if 20 to 40% humeral head involvement or humeral head arthroplasty if humeral head lesion is greater than 40% of the humeral head

## “Subtle” Posterior Instability

- Incidence in active duty population is up to 24% (Song et al, JSES, 2015) and 23% in our MOON population (Krautler et al, AJSM, 2018)
- Common in football linemen, hockey players, throwing athletes, divers, gymnasts, shooting sports
- Pain and popping (e.g. with weight lifting/football blocking) (90%) > instability (13%)

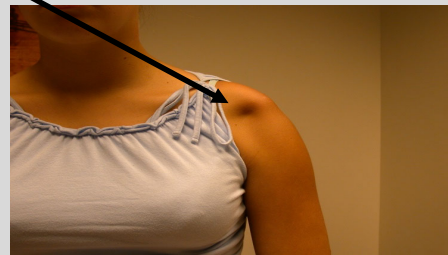



## Multi-Directional Instability (MDI)

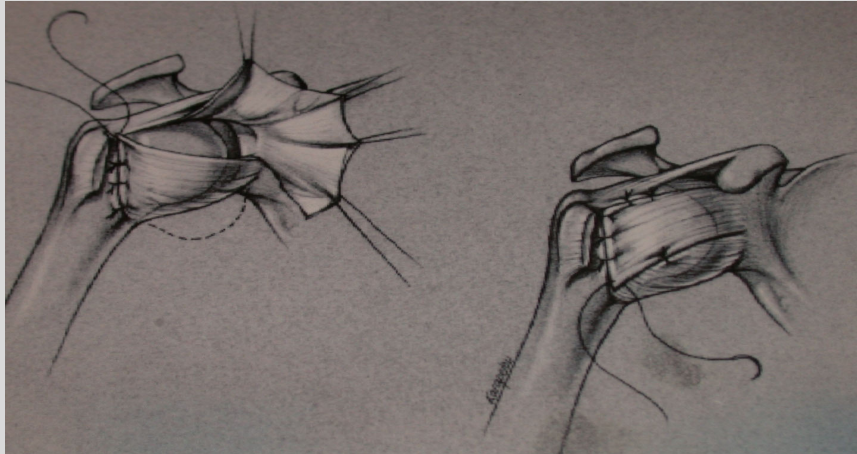
- Young patient with hyperlaxity of multiple joints (patellar instability, contralateral shoulder instability, hyperextension of elbow joints and metacarpal-phalangeal joints)
- Positive inferior sulcus sign
- Usually atraumatic etiology
- Treatment is a long course of PT working on strengthening the dynamic stabilizers of the shoulder
- Great majority of MDI patients respond to a PT program as long as they are compliant
- Surgery is last resort if failure of greater than 6 months of appropriate conservative management

## Positive Inferior Sulcus Sign

- Reduced joint
- Positive inferior sulcus sign



## Surgery- Open Inferior Capsular Shift Versus Arthroscopic Plication



## Voluntary Dislocation

- Young, adolescent patients
- Psychiatric disorder or recent psychologic trauma
- Common scenario- successful closed reduction in ER, but shoulder dislocates on way to X-ray
- Treatment- educate patient that their instability is muscular controlled; obtain psych counseling